Herpes Simplex Virus Infections of the Central Nervous System: Encephalitis and Meningitis, Including Mollaret's

Kenneth L Tyler, Department of Neurology, University of Colorado Health Sciences Center and Denver Veterans Affairs Medical Center, Denver, Colorado, USA.

KEY WORDS

HERPES SIMPLEX VIRUS ▮ CENTRAL NERVOUS SYSTEM ▮ ENCEPHALITIS ▮ MENINGITIS ▮ MOLLARET'S MENINGITIS ▮ MANAGEMENT RECOMMENDATIONS

SUMMARY

Herpes simplex encephalitis (HSE) is a life-threatening consequence of herpes simplex virus (HSV) infection of the central nervous system (CNS). Although HSE is rare, mortality rates reach 70% in the absence of therapy and only a minority of individuals return to normal function. Antiviral therapy is most effective when started early, necessitating prompt diagnosis. The *International Herpes Management Forum* (IHMF) has issued guidelines to aid the diagnosis and treatment of HSE. Polymerase chain reaction (PCR) of the cerebrospinal fluid (CSF) is the diagnostic method of choice for HSE, but negative results need to be interpreted in the context of the patient's clinical presentation and the timing of the CSF sampling. CSF virus culture is of little value in all but patients under the age of 6 months. CSF (intrathecal) antibody measurements are not recommended for acute diagnostic purposes. However, demonstration of an intrathecal HSV antibody response may be helpful in retrospective diagnosis or in cases in which CSF is sampled only late after onset of infection and PCR is negative. Serum HSV antibody measurements are not of utility in the diagnosis of HSV encephalitis in adults. In children and young adults, HSV serology may help define whether HSE is part of a primary or a reactivated HSV infection, although the clinical features, therapy, and prognosis of these two forms of HSV encephalitis are similar. The IHMF recommends that all patients with HSE receive intravenous aciclovir 10 mg/kg every 8 h for 14–21 days. Owing to the life-threatening nature of the disease, if there is a delay in diagnostic test results therapy should not be withheld until they become available. After completion of therapy, PCR of the CSF can confirm the elimination of replicating virus, aiding further management of the patient. Clinical trials of other antiviral agents (i.e. adjunctive oral valaciclovir after intravenous aciclovir) for the treatment of HSE are underway. Herpes infection of the CNS, especially with HSV-2, can also cause both monophasic and recurrent aseptic meningitis, as well as myelitis or radiculitis. Limited evidence suggests that aciclovir may be effective in its treatment. Recurrent aseptic meningitis is predominantly caused by HSV-2 infection, and is characterized by self-limited episodes of fever, meningismus and severe headache. Many cases are indistinguishable from cases previously classified as "Mollaret's meningitis", a term that should now be reserved for idiopathic cases of recurrent aseptic meningitis.

Introduction

HERPES SIMPLEX VIRUS (HSV) infection of the central nervous system (CNS) occurring in the neonatal period (<1 month of age), causes neonatal herpes, while in older children and adults it can manifest as either life-threatening herpes simplex encephalitis (HSE) or the more benign aseptic meningitis. HSV infection can also cause recurrent aseptic meningitis, with or without myelitis or radiculitis. Recurrent HSV meningitis is essentially indistinguishable from cases of recurrent meningitis previously classified as 'Mollaret's meningitis'. The term Mollaret's meningitis should now be reserved for idiopathic cases of recurrent aseptic meningitis, whereas cases of recurrent meningitis known to be associated with HSV should be referred to as recurrent HSV meningitis. This paper reviews the epidemiology, diagnosis and management of HSV-related diseases of the brain: encephalitis (HSE) and meningitis.

HSE

EPIDEMIOLOGY OF HSE

Herpes simplex encephalitis is the most common cause of acute sporadic encephalitis in children older than 6 months of age and in adults.[1,2] No seasonal or gender-related variability occurs in the incidence of HSE cases,[3] which differentiates it from encephalitis due to other causes (e.g. arbovirus encephalitis). HSE occurs relatively infrequently with an incidence of only one case per 250 000 population/year in the USA and in 2.5 per 1 million population/year in Sweden.[4,5] In the absence of therapy, mortality exceeds 70% and prognosis is poor as only a minority of individuals return to normal function.

There is a bimodal distribution of HSE, with one third of cases occurring in those less than 20 years old and one half in those aged 50 years or more. In a recent polymerase chain reaction (PCR) study of 516 patients with clinical evidence of encephalitis, 7.4% of cases were due to HSV infection and most HSE cases were in those 40 years of age or older.[6] The peak incidence of HSE occurred in subjects aged between 60 and 64 years; for whom HSV accounted for 37.5% of all cases of encephalitis.[6] The bimodal age distribution may reflect primary HSV infection in the younger age group and reactivation of latent HSV in older patients.[6]

In immunocompetent adults, >90% of cases of HSE result from infection with HSV-1, with the remainder due to HSV-2 infection.[7] More than two thirds of cases of encephalitis due to HSV-1 appear to result from reactivation of endogenous latent HSV-1 in individuals previously exposed to the virus; the remaining cases seem to be the result of primary infection in those without evidence of prior exposure to HSV.[3,8] Cases of HSV-2 encephalitis probably reflect primary infection rather than reactivation.[7] A number of cases of adult HSV-2 meningoencephalitis have been reported in patients with AIDS.[9,10]

RECOMMENDATIONS AND STATEMENTS

- Patients with HSE should receive intravenous aciclovir (10 mg/kg every 8 h for 14–21 days) (category 1 recommendation)
- PCR of the cerebrospinal fluid (CSF) is the diagnostic method of choice for HSE and therapy should be instituted pending the results of PCR (category 1 recommendation)
- Virus cultures are of little value for the diagnosis of HSE in older children (>6 months) and adults (category 1 recommendation)
- CSF antibody measurements are not recommended for acute diagnosis of HSE. CSF antibody measurements may be useful in retrospective diagnosis or in cases in which CSF was obtained only at late times following illness onset and is PCR negative (category 1 recommendation)
- PCR of the CSF should be considered at completion of therapy for HSE to monitor treatment response (category 2 recommendation)
- Antiviral therapy may be discontinued if a negative CSF HSV PCR test is obtained at >72 hours following onset of neurological symptoms from a patient with a low probability of having HSE (e.g. normal neuroimaging, <5 cells/mm^3 in CSF and normal level of consciousness) (category 3 recommendation)
- Therapy of recurrent aseptic HSV meningitis should be individualized according to the number and severity of recurrences (category 3 recommendation)
- As mortality rates remain high in spite of judicious aciclovir therapy, there is a need for improved management of HSE (research need recommendation)
- New therapeutic protocols, such as anti-inflammatory agents and anti-apoptotic agents should be explored (research need recommendation)

RECOMMENDATION AND STATEMENT CATEGORIES

Category 1

Consistent evidence from controlled clinical trials. For example, for an antiviral, this would include results from at least one well-designed, randomized, controlled clinical trial, and, in the case of laboratory studies, consistent evidence from comparative studies.

Category 2

Evidence from at least one well-designed clinical trial without randomization, from cohort or case-controlled analytical studies (preferably from more than one centre), or from multiple time-series studies or dramatic results from uncontrolled experiments.

Category 3

Evidence from opinions of respected authorities based on clinical experience, descriptive studies or reports of expert committees.

Research Need

Area in which research is warranted.

PATHOGENESIS OF HSE

Primary oropharyngeal HSV-1 infection results in axoplasmic transport of virus to the trigeminal sensory ganglion, where it establishes latency. Latent HSV-1 is detectable in the trigeminal ganglia of virtually all seropositive individuals.[11] Reactivation leads to retrograde transport of virus, resulting in herpes labialis, among other clinical manifestations.

In animal models, HSV can enter the CNS through the olfactory tract.[12] However, the pathway by which HSV reaches the CNS to produce encephalitis in humans following either primary or reactivational infection remains unclear. One possibility is that reactivated virus in trigeminal ganglia, rather than spreading via its usual route to the face or lip to produce herpes labialis, may on rare occasions spread via tentorial nerves to the anterior and medial cranial fossa.[13] In the case of primary infection, virus could invade the olfactory bulbs through the nose, and spread via olfactory pathways to the orbitofrontal and medial temporal lobes.[14] HSV DNA can be amplified using PCR from a variety of regions in the CNS including the brainstem, olfactory bulbs, gyrus rectus and limbic areas at post-mortem in approximately one third of HSV seropositive asymptomatic individuals without known neurological disease.[11,15] It remains unknown whether this genome reflects the presence within the CNS of latent HSV with retained capacity to reactivate.

HSV-2 infection most often results in genital herpes, with the virus establishing latency in the sacral dorsal route ganglia; this strain can also infect the mouth, following oral-genital sex, and be reactivated to cause facial herpes. Other manifestations of HSV-2 infection (e.g. herpetic whitlow) are much less common. HSV-2 infection of the CNS can manifest as subacute encephalitis (particularly in patients with AIDS), acute HSE, meningitis or recurrent meningitis, and myelitis. The neuronal pathways that lead to infection of the CNS are not, as yet, defined.

DIAGNOSIS OF HSE

- PCR of the CSF is the diagnostic method of choice for HSE and therapy should be instituted pending the results of PCR (category 1 recommendation)
- CSF antibody measurements are not recommended for acute diagnosis of HSE. CSF antibody measurements may be useful in retrospective diagnosis, or in cases in which CSF was obtained only at late times following illness onset and is PCR negative (category 1 recommendation)
- Virus cultures are of little value for the diagnosis of HSE in older children (>6 months) and adults (category 1 recommendation)
- Antiviral therapy may be discontinued if a negative CSF HSV PCR test is obtained at >72 h following onset of neurological symptoms from a patient with a low probability of having HSE (e.g. normal neuroimaging, <5 cells/mm^3 in CSF and normal level of consciousness) (category 3 recommendation)

Early diagnosis of HSE is important, as antiviral therapy is clinically effective in both treating the disease and improving morbidity and mortality outcomes. However, diagnosis is difficult because of the non-specificity of initial signs and symptoms. Intrathecal antibody measurements are not recommended for acute diagnostic purposes. However, intrathecal HSV antibody responses may be useful in retrospective diagnosis or in cases in which CSF was obtained only at late times post-infection and was PCR negative. Serum HSV antibody measurements are of no utility in acute diagnosis of HSV encephalitis. In children and young adults, initial serum HSV antibody measurements may be useful in distinguishing primary from reactivated HSV infection, although there are currently no clear differences in the diagnosis, clinical features, treatment or prognosis of primary versus reactivational HSV encephalitis.

Diagnosis of HSE: clinical manifestations: Herpes simplex encephalitis is characterized by acute focal, necrotizing encephalitis with inflammation and swelling of the brain tissue. Patients with meningitis typically have headache, nuchal rigidity and fever, but not altered sensorium or focal neurological findings.[16]

One PCR study has evaluated the range of clinical presentations of encephalitis in a case series of encephalitis of different aetiologies.[17] Patients were

grouped into those with focal, diffuse and mild encephalitis. Patients with focal disease had weakness, sensory abnormalities, aphasia, visual field defects or cranial nerve palsies and/or localized abnormalities on neuroimaging studies. Patients with diffuse disease had a decreased level of consciousness and neurobehavioural changes, but did not have focal abnormalities on neurological examination or localized abnormalities on neuroimaging. Patients with mild encephalitis were distinguished from the focal and diffuse groups predominantly by their relatively preserved level of consciousness (Glasgow Coma Scale ≥13).

Herpes simplex virus was a major cause of encephalitis in this study, being responsible for approximately 37% of cases (Table 1). When the different presentations of encephalitis were considered, HSV was found to be the cause of 52% of the focal encephalitis cases, 25% of the mild cases, and none of the diffuse cases. Thus HSV is commonly associated with the development of focal encephalitis but is less likely to produce diffuse or non-focal disease. Despite this, the possibility of HSV infection should still be considered, even in patients with mild or atypical presentations of encephalitis.[17]

Diagnosis of HSE: PCR: The widespread use of PCR amplification of HSV DNA has led to a change in our understanding of the signs and symptoms of HSE and has dramatically broadened the recognized spectrum of HSV-related infections of the CNS. Prior to the advent of PCR, brain biopsy with virus isolation – which has a specificity of 100% – was the accepted standard for diagnosis.

In most cases of HSE, HSV DNA is present in CSF and can be detected by PCR.[18–22] In the two most comprehensive studies to date, PCR of CSF was compared with brain biopsy[22] or brain biopsy and intrathecal HSV serology.[19] CSF PCR was positive in 53 of 54 patients (98%) with biopsy-proven HSE, and negative in 94% of biopsy-negative cases. Based on this study, PCR has a sensitivity of 98%, a specificity of 94%, a positive predictive value of 95% and a negative predictive value of 98%.[22] In 43 consecutive HSE cases verified by HSV in brain biopsy or necropsy and/or intrathecal HSV IgG antibody production, and in 60 patients with acute febrile focal encephalopathy (initially suspected to be HSE but excluded by the absence of intrathecal HSV antibody synthesis), 238 CSF samples were tested. PCR detected HSV DNA in 42 of the 43 patients with HSE; all but one were positive in the first CSF. All the control subjects were PCR negative.[19]

The results of CSF HSV PCR should always be evaluated in the context of the pre-test likelihood that a patient has HSE. In patients with a low prior probability of HSE, a negative CSF HSV PCR result reduces disease likelihood to <1%. However, in patients with a high prior probability of HSE (e.g. an individual with typical EEG and MR findings and a CSF pleocytosis), a negative test only reduces disease likelihood to ~5%, but does not exclude it entirely. It is important to consider these issues carefully when deciding whether to discontinue antiviral therapy based on PCR results. It has also recently been suggested that false-negative CSF PCR tests may occur when testing is performed at ≤72 h post-onset of symptoms. In these patients, caution should be exercised in discontinuing antiviral therapy unless an alternative diagnosis has been established or a repeat CSF PCR test obtained at ≥72 h has also been negative. Additional causes of false-negative CSF HSV PCR results include the presence in CSF of porphyrin compounds derived from the degradation of haeme in erythrocytes.[19] As a result, caution should be used in interpreting negative PCR results in bloody CSF specimens.

When present, HSV DNA is detectable by PCR in the CSF for at least 1 week after symptom onset in most patients with HSV-related infection of the CNS.[23] In one study, 100% PCR positivity has been reported when CSF was collected within 10 days after onset of symptoms, 30% for samples collected on Days 11–20, and 19% for samples collected on Days 21–40 (Figure 1).[23] CSF PCR results in 42 HSE cases are shown in Figure 2.[19]

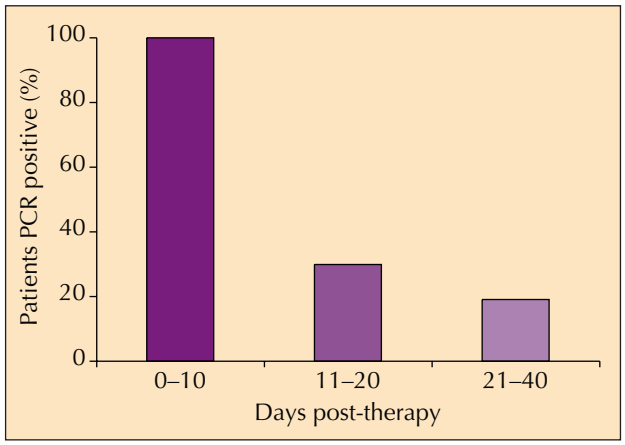

Figure 1:
Detection of HSV DNA in the CSF following onset of symptoms[23]

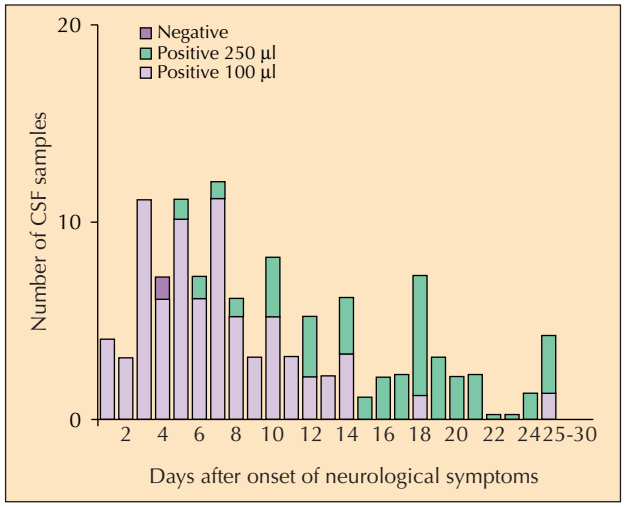

Figure 2:
PCR results in relation to time from onset of neurological symptoms in CSF samples from 42 PCR-positive patients with herpes simplex encephalitis. None of the 36 samples at 30 days or more was positive.[19] *Reprinted with permission from Elsevier (*The Lancet *1991;***337:***189–192).*

Table 1: Results of PCR analysis of CSF samples from patients with encephalitis[17]

	Patients *n* (%)			
PCR result	**Focal encephalitis**	**Diffuse encephalitis**	**Mild encephalitis**	**Total**
HSV-positive	15 (51.7)	0	3 (25)	18 (36.7)
HSV-negative	14 (48.3)	8 (100)	9 (75)	31 (63.3)
Total	29 (100)	8 (100)	12 (100)	49 (100)

Reproduced with permission from Domingues RB, Tsanaclis AM, Pannuti CS *et al*. Evaluation of the range of clinical presentations of herpes simplex by using polymerase chain reaction assay of cerebrospinal fluid samples. *Clin Infect Dis* 2000;**31**:894–903. © by The University of Chicago. All rights reserved.

The incidence of false-positive CSF PCR results for HSV is extremely low when the technique is performed in laboratories using accepted standards as well as appropriate controls and methods to avoid contamination. Improper procedures resulting in sample-to-sample contamination have been the cause of isolated examples of high numbers of false-positive tests from particular laboratories.[24]

Comparison of the clinical features of PCR-diagnosed HSE with biopsy-proven HSE: The clinical features of PCR-defined HSE are generally similar to those for biopsy-proven disease,[3,17] although the overall severity of disease in PCR-proven cases appears to be less than in a biopsy-proven series. This difference may reflect the greater sensitivity of PCR, which identifies a greater number of less severe cases than biopsy.[3,17] This is most obvious in the Glasgow Coma Scale; only 35% of biopsy cases have a score of >10 compared with nearly 80% of CSF PCR diagnosed cases. Importantly, approximately 15–20% of patients identified as having mild or atypical forms of HSE by PCR would almost certainly have been unrecognized previously. Similarly, personality change was less common in the PCR-defined subgroup, being evident in approximately 60% of cases, versus 70–85% in biopsy studies.[3,17] Seizures occurred in 50% of PCR-positive and 40% of biopsy-positive cases.[3,17] Deficits in motor function were seen in approximately one third of cases in both groups.[3,17] However, aphasia appears to be more common in biopsy- than in PCR-positive cases (75% versus 31%).[3,17] In the Swedish multicentre study of aciclovir versus vidarabine for the treatment of HSE, personality changes occurred in 87%, seizures in 62%, hemiparesis in 40% and aphasia in 36% of the cases.[5]

Quantitative PCR in HSE: Quantitative HSV PCR may have value in determining prognosis of HSV encephalitis.[25,26] In one study,[25] morbidity and mortality were greater in patients with >100 HSV DNA copies/mm^3 of CSF (high copy number) than in those with lower levels. In general, larger amounts of HSV DNA were found in CSF of patients with a longer duration of symptoms; patients with a high copy number had a mean of 6.5±3 days of symptoms compared to 3.8±3 days for those with less DNA in their CSF. Disease severity also differed according to the quantity of CSF DNA; a reduced level of consciousness was documented in all patients with a high copy number compared with only 43% of those with a low copy number. All patients with a high copy number also had computed tomography (CT) scan abnormalities compared with only 15% of patients with a low copy number. Overall, patients with a high copy number had a significantly worse prognosis than those with a low copy number. In those with a high copy number, mortality was 11%, and 63% of the survivors had moderate or severe impairment at 3-month follow-up. By contrast, all patients with low copy number survived, and 86% had normal function at 3-month follow-up.[25] In a second study, HSV-1 load in the CSF did not clearly correlate with the severity of clinical signs or the degree of cranial imaging findings and overall outcome.[26] However, as discussed below, the amount of HSV-1 DNA in the CSF decreased with aciclovir therapy.

Although PCR analysis of CSF for HSV DNA is the gold standard for diagnosis of HSE, supportive techniques such as neuroimaging, electroencephalography (EEG) and examination of the CSF may also be beneficial in establishing the likelihood of the disease.

Diagnosis of HSE: examination of the CSF: Cerebrospinal fluid analysis demonstrates elevated mononuclear cells and protein. A lymphocytic pleocytosis of between 10 and 500 cells/mm^3 occurs in 85% of HSE patients; less than 8% of patients with biopsy- or PCR-proven disease will have a normal CSF cell count.[3,17,27] Elevated protein (60–700 mg/dl) is found in 80% of patients, with values >800 mg/dl rarely encountered.[3] In some patients, red blood cells (10–500 cells/mm^3) are present or there may be a mild hypoglycorrhachia (30–40 mg/dl glucose). The CSF rarely contains HSV that can be grown in culture.[8]

Diagnosis of HSE: neurodiagnostic tests: Neurodiagnostic tests used for the diagnosis of HSV infections of the CSF include magnetic resonance imaging (MRI) and EEG.

Normal MRIs have been reported in approximately 10% of PCR-positive patients, but the remainder will have temporal lobe abnormalities. MRI is often abnormal early on in the clinical course of HSE, showing damage to the blood–brain barrier with oedema and necrosis in the temporal lobe[17,28] as well as characteristic high signal intensity lesion on T_2-weighted images in the medial and inferior temporal lobe extending up into the insula. Abnormalities may be seen on diffusion-weighted or FLAIR images when conventional sequences are normal or show only minimal lesions.[29] Lesions are rarely seen in the basal ganglia, brainstem or cerebellum.

Electroencephalography provides only limited diagnostic information; non-specific slow-wave activity is seen during the first 5–7 days of illness followed by paroxysmal sharp waves or triphasic complexes with a temporal predominance.[30–34] Some patients develop periodic lateralizing epileptiform discharges (PLEDs) at a rate of 2–3 Hz originating from the temporal lobe.[32] Although PLEDs are not disease defining, they suggest a diagnosis of HSE. PLEDs may be absent very early in the course of disease, and their absence does not exclude or significantly reduce the likelihood of HSE. Resolution of EEG abnormalities does not correlate well with clinical recovery.[34]

CLINICAL TRIALS OF ANTIVIRAL THERAPY IN HSE

- Patients with HSE should receive intravenous aciclovir (10 mg/kg every 8 h for 14–21 days) (category 1 recommendation)
- As mortality rates remain high in spite of judicious aciclovir therapy, there is a need for improved management of HSE (research need recommendation)
- New therapeutic protocols, such as anti-inflammatory agents and anti-apoptotic agents should be explored (research need recommendation)

Aciclovir therapy of HSE in adults: The current standard of care for HSE in adults and children over 3 months of age is intravenous aciclovir (10 mg/kg every 8 h for 14–21 days), which has superseded vidarabine. In a randomized, double-blind, placebo-controlled study, intravenous vidarabine (15 mg/kg per day for 10 days) significantly reduced mortality from 70% to 28% in 28 patients with biopsy-proven HSV-1 encephalitis; at 6 months the mortality in the vidarabine group was 44%.[35] However, vidarabine therapy was associated with neurological and gastrointestinal toxicity in patients with impaired renal function or chronic hepatitis. In practice, aciclovir is used because of its superior efficacy and safety profile compared with vidarabine.

The superior efficacy of aciclovir over vidarabine was demonstrated in two comparative trials in which HSE-related mortality was reduced by a greater extent with aciclovir. In the trials, patients with HSE were randomized to receive 10 days' treatment with either vidarabine (15 mg/kg per day) (n=37 and n=24) or aciclovir (30 mg/kg per day) (n=32 and n=27).[5,36] The mortality rates at 6 months were 50–54% in vidarabine-treated patients compared to 19% in aciclovir-treated patients (P=0.008).[5,36] At 18 months, mortality in the vidarabine recipients was 54%, while in the aciclovir

group it was 28% (P=0.008).[36] The outcome at 6 months was also better for the aciclovir recipients in the two trials; in surviving patients, normal function was achieved in 38–56% of those who received aciclovir compared with only 13% of vidarabine-treated patients (P=0.021). It is on the basis of these results that aciclovir is the mainstay of treatment for HSE but morbidity and mortality remain high even with treatment, and many patients require long-term supportive care.[5,36]

More recent studies of aciclovir therapy recorded mortality rates of between 6% and 11%. The lower mortality in these trials compared with the earlier comparative trial of aciclovir and vidarabine may be because HSE was diagnosed by CSF PCR.[17,25] If diagnosis had been by biopsy, more severe cases, with a poorer outcome, would have been included in the studies.

Aciclovir therapy of HSE in paediatric patients: One retrospective analysis of paediatric patients with HSE has evaluated mortality and morbidity outcomes following treatment with aciclovir.[37] Of 28 children aged 9 months to 16 years (mean age approximately 7 years) who were treated with aciclovir 30 mg/kg per day (every 8 h) for 10 days, 10 had persistent neurological sequelae and two died.[37]

Other antivirals in clinical trials for therapy HSE: A randomized, clinical trial of adjunctive oral valaciclovir following a standard intravenous course with aciclovir for the treatment of HSE is currently being conducted by the Collaborative Antiviral Study Group (CASG 204). All patients receive intravenous aciclovir therapy for 14–21 days, followed by either oral valaciclovir or placebo for 90 additional days. The study is designed to determine whether more prolonged antiviral therapy will improve outcome, including neuropsychological function in patients.

Factors influencing treatment outcome: Factors influencing the outcome of aciclovir therapy in adults and children include:

- Age
- Level of consciousness at presentation
- Duration of encephalitis
- Viral load.

For example, if the level of consciousness at presentation is 6 points or less on the Glasgow Coma Scale, a poor therapeutic outcome is uniform, irrespective of the age of the patient. If the duration of the disease before initiation of therapy is 4 days or less, then survival at 18 months increases from 72% to 92%.[36]

Frequency of relapse: The number of adults or older children who relapse following treatment with aciclovir is uncertain. Reports in paediatric series have indicated that this may occur in as many as 5–26% of aciclovir-treated patients[38,39] although the incidence in adults appears to be toward the lower end of this range. In one study of 27 children with PCR-diagnosed and aciclovir-treated HSE, seven (26%) had a relapse of encephalitic illness.[39] In two of those seven, HSV DNA reappeared temporarily in the CSF. In all seven patients, a second course of aciclovir therapy was associated with a reduction in signs and symptoms. By contrast, relapse of HSE (five episodes) was diagnosed in three of 26 (12%) consecutive aciclovir-treated adult HSE patients. HSV-DNA was not demonstrable in any of 13 CSF samples taken during relapses. A pronounced proinflammatory immunological response in CSF and the lack of demonstrable HSV-DNA in CSF during relapse suggested that immunologically mediated effects were of greater importance than persistent or reactivated viral infection in relapses of HSE in these patients.

Relapses generally occur 1 week to 3 months after initial improvement following completion of 10–14 days of aciclovir therapy. In cases of post-viral immune-mediated encephalomyelitis, CSF PCR is negative, no virus is detectable in the brain, and neuroimaging and/or pathological studies may indicate the presence of demyelination. By contrast, patients with relapses due to active viral infection have virus detectable in the brain and and may be CSF PCR positive. It is not known whether the sensitivity of PCR in detecting relapses is equivalent to its sensitivity in acute HSV encephalitis, but the presence of a positive CSF PCR suggests that relapse is due to persistent viral infection rather than a post-infectious immune-mediated process. The relative frequency of these two types of relapse (persistent or reactivated viral infection versus post-infectious immune mediated disease) is unknown.

Patients with clinical relapse of HSE and positive CSF HSV PCR should be retreated with a standard course of aciclovir. The utility of aciclovir treatment in patients without evidence of active viral infection (e.g. a positive CSF PCR or isolation of virus from brain biopsy) has not been established. Although virus isolated from brain biopsies of patients with HSE who have relapsed has not proved to be aciclovir resistant, testing of isolates for aciclovir sensitivity may be useful under certain circumstances.[40]

PCR monitoring of therapy:

- PCR of the CSF should be considered at completion of therapy for HSE to monitor treatment response (category 2 recommendation)

Antiviral therapy appears to lower the amount of HSV DNA in the CSF. In a study of vidarabine treatment of HSE, there was no change in the rate of detection of HSV DNA in CSF in patients receiving less than 1 week of therapy.[22] However, after 8–14 days of therapy, only 47% of specimens remained positive for DNA, while the corresponding figure for those receiving more than 2 weeks of therapy was 21%. In most cases, aciclovir treatment of HSE leads to a sharp decline in the number of PCR-positive cases after 2 weeks,[7,19,20,25,27,41] with HSV DNA rarely detected after 30 days.[20,27,41] It is therefore suggested that CSF PCR should be performed upon completion of 10–14 days aciclovir therapy, and that any patient who has detectable HSV DNA in their CSF should receive an additional course of therapy.[42]

Quantitative PCR may have a role in monitoring response to therapy, although evaluation has been limited. In one study of eight HSE patients,[26] prior to treatment HSV-1 DNA was detected at a mean value of 1786 copies/10^5 cells. During intravenous aciclovir therapy, the quantity of HSV-1 DNA decreased gradually to a mean value of 6 copies/10^5 cells within 6–21 days and disappeared, or was barely detectable, before treatment completion in most cases.[26]

Recurrent Aseptic Meningitis

CLINICAL MANIFESTATIONS

Symptoms of meningitis occur frequently during primary genital herpes, being reported in 36% of women and 11% of men.[43] Approximately 20% of patients with an initial episode of HSV-2 meningitis will go on to have a recurrence.[44] Symptoms typically disappear after several recurrences, usually spanning a period of years. Transient neurological abnormalities (seizures, cranial nerve paresis, pathological reflexes) occur in some patients. During the first year after (HSV-2) meningitis, nearly half of 40 consecutive patients had verified or suspected neurological recurrences.[45] Eleven patients experienced concurrent or separate episodes of recurring mucocutaneous and neurological symptoms, seven had neurological recurrences only and five had only mucocutaneous recurrences.

Recurrent aseptic meningitis (also called Mollaret's meningitis) is a syndrome occurring more commonly in

women than men and is characterized by repeated self-limiting episodes of fever, meningismus and severe headache (usually of 2–5 days' duration) separated by symptom-free intervals.[46,47] Most cases of Mollaret's meningitis are caused by HSV-2. CSF obtained in the first 24 h of the illness may occasionally show characteristic large mononuclear cells, termed 'Mollaret's cells'. It is important to realize that the definition of a Mollaret cell is somewhat arbitrary, as cell-type specific markers for these cells are not available. Mollaret cells may be absent in patients with 'Mollaret's' meningitis, and otherwise typical cells have been found in other disorders (e.g. recurrent meningitis due to periodic discharge of the contents of an epidermoid tumour into the subarachnoid space). Cells indistinguishable from Mollaret cells may also be seen in other viral infections (e.g. West Nile virus meningitis or encephalitis).

The incidence of recurrent aseptic HSV meningitis is difficult to determine; in older studies, in which it was associated with various herpesviruses on the basis of clinical and/or serological findings, HSV was suggested to account for 1–3% of cases, but this is likely to be a significant underestimate.[48,49]

Patients presenting with recurrent aseptic meningitis are often reported to have a history of genital herpes.[45,47,50,51] However, an estimated 60% of patients with PCR-confirmed recurrent aseptic HSV meningitis do not have a previous history of genital lesions.[47,48,51,52] For example, episodes of both recurrent meningitis and clinical encephalitis have been reported in a male patient with no history of genital herpes, but evidence of HSV infection by PCR.[52] Similarly, HSV-2 DNA was detected by PCR in the CSF of nine patients with recurrent aseptic meningitis during an attack; six of these had no history of genital herpes.[51]

DIAGNOSIS OF RECURRENT ASCEPTIC MENINGITIS

Characteristic CSF findings during a first episode of meningitis include a lymphocytic pleocytosis, elevated protein and normal glucose. In a study of 27 patients with a first episode of HSV-2 meningitis, average CSF values were 431 cells/mm^3 (85% lymphocytes), 160 mg/dl protein and 54 mg/dl glucose.[44] In comparison, patients with recurrent episodes of meningitis had lower cell counts (mean: 280/mm^3), less protein (mean: 100 mg/dl) and a higher CSF glucose concentration (mean: 63 mg/dl).[44]

CSF culture, in distinction to the result in HSE, may be positive for HSV-2 in approximately 75% of initial episodes of meningitis associated with primary HSV infection, but is invariably negative in recurrent attacks.[44] Demonstration by CSF PCR of HSV-2 DNA is extremely sensitive and specific in diagnosis of both initial and recurrent episodes of HSV meningitis, and should be considered the diagnostic procedure of choice. Demonstration of seroconversion to HSV-2 in primary HSV-2 meningitis and of intrathecal synthesis of HSV antibodies in recurrent HSV meningitis may also assist in diagnosis. A history of prior or concomitant episodes of genital herpes in a patient with recurrent aseptic meningitis should suggest the possibility of recurrent HSV meningitis, although many patients will not have clinical evidence of genital lesions at the time of an attack of meningitis.

In 27 patients with a first episode of HSV-2-induced meningitis, confirmed by virus isolation from the CSF, neurological complications were found in 10 (37%) but subsided before 6 months in all patients. Long-term complications included recurrent meningitis in five (19%) and periodic headache related to genital HSV recrudescences in four (15%). Seven additional patients had possible HSV-2-induced recurrent meningitis. In contrast to the first episode of meningitis, virus isolation, HSV antigen detection and IgG analyses in consecutive serum samples were of no diagnostic value in episodes of HSV-2-induced recurrent meningitis.

Patients with benign recurrent lymphocytic meningitis generally fit accepted diagnostic criteria for Mollaret's meningitis. Typically, CSF specimens obtained 1–2 days following the onset of recurrent HSV meningitis do not contain Mollaret's cells; and there is a lymphocytic pleocytosis from onset, rather than an initial polymorphonuclear pleocytosis with subsequent transition to lymphocytes. Therefore, some authors have proposed that this condition is distinct from Mollaret's meningitis.[53] However, the term Mollaret's meningitis has more typically been used to refer to recurrent episodes of aseptic meningitis. One prospective cohort study and one report of two cases have established that HSV infection is the major cause of the syndrome of recurrent aseptic meningitis.[53,54]

In the cohort study, CSF was prospectively collected from 20 patients with a provisional diagnosis of benign recurrent aseptic lymphocytic meningitis.[53] Eleven of 13 (85%) patients with confirmed benign recurrent lymphocytic meningitis had evidence of HSV DNA and of intrathecal HSV antibodies in CSF; these were absent in a group of patients with meningeal inflammatory illnesses due to other aetiologies. HSV-2 was the predominant virus type found in the patients with benign recurrent lymphocytic meningitis, although one case was due to HSV-1. Only one patient had antibody to both HSV-1 and -2, suggesting that HSV-2 antibody in CSF is the result of intrathecal synthesis and not passive transfer of serum antibody resulting from breakdown of the blood–brain barrier.[53] Similarly, in a case report, HSV-2 DNA was detected by PCR in the CSF of two patients with recurrent aseptic lymphocytic meningitis.[54]

ANTIVIRAL THERAPY IN RECURRENT ASEPTIC MENINGITIS

- Therapy of recurrent aseptic HSV meningitis should be individualized according to the number and severity of recurrences (category 3 recommendation)

Anecdotal evidence suggests that aciclovir is effective in the treatment of Mollaret's meningitis, although randomized trials have not been published. The majority of patients remain symptom-free for many years, suggesting that long-term antiviral prophylaxis may not be appropriate. However, intermittent or continuous prophylaxis may be considered for frequent episodes.

Several reports have described the use of aciclovir for the treatment of primary and recurrent HSV-related meningitis in the presence of HSV-2-associated genital lesions.[55] In five case reports, symptoms were resolved within 72 h of treatment with intravenous aciclovir (5–10 mg/kg three times daily).[48,56,57] In one report, two patients who developed meningitis after the HSV-2-positive primary genital lesions were treated with intravenous aciclovir (5 or 10 mg/kg three times daily) for 7 or 10 days. Rapid improvement was reported in signs and symptoms of meningitis.[55] This approach, while only based on an anecdotal report, may be of value for individuals with frequent recurrences.

The case histories reported to date, employed mainly intravenous therapy, but the limited evidence available suggests that oral agents are also effective, especially for individuals with frequent recurrences.[55] Alternative agents such as valaciclovir and famciclovir are likely to be equally efficacious. A randomized, multicentre, clinical trial of long-term suppressive oral valaciclovir following HSV-2 meningitis is currently underway in Sweden.

Benign Recurrent Lymphocytic Meningitis

Patients with benign recurrent lymphocytic meningitis generally fit accepted diagnostic criteria for Mollaret's meningitis. Typically, CSF specimens obtained 1–2 days following the onset of illness do not contain Mollaret's

cells; and there is a lymphocytic pleocytosis from onset, rather than an initial polymorphonuclear pleocytosis with subsequent transition to lymphocytes. Therefore, some authors have proposed that this condition is distinct from Mollaret's meningitis.[53]

Conclusions

Herpes simplex encephalitis is associated with a high mortality rate (approximately 70% in untreated patients), and only 2.5% of surviving patients return to normal neurological function in the absence of therapy. Most (>90%) cases of HSE in children and adults are due to HSV-1. More than two thirds of HSV-1-related HSE cases result from reactivation of endogenous latent HSV-1 in individuals previously exposed to the virus; the remaining cases appear to be the result of primary infection in individuals without evidence of prior exposure to HSV.

Herpes simplex virus infection is most commonly associated with the development of focal encephalitis, but can produce diffuse, non-focal disease. Therefore, the possibility of HSV infection should be considered even in patients with mild or atypical presentations of encephalitis.

Early diagnosis of HSE is important, as antiviral treatment is clinically effective in both treating the disease and improving morbidity and mortality outcomes. PCR analysis of CSF for HSV DNA is recommended for the diagnosis of HSE, although supportive techniques such as neuroimaging, EEG and examination of CSF may also be beneficial. PCR has >95% sensitivity and specificity for HSV DNA in the first week after treatment onset for patients with HSE. Negative CSF HSV PCR results need to be interpreted in the context of the patient's clinical condition, and the timing of the test in relation to the onset of disease.

Early treatment (of suspected HSE) with aciclovir may reduce mortality and allow significant restoration of cognitive function in all but the most severe cases. The best response to therapy is seen in patients with the least neurological impairment at the initiation of treatment.

Relapse may occur in 5–26% of paediatric patients with HSE and in a smaller percentage of adult cases. CSF PCR may help distinguish reactivation due to active viral infection from immune-mediated syndromes. Patients with active infection should receive a repeat course of aciclovir therapy.

Herpes simplex virus-2 is the most common identified cause of both Mollaret's meningitis and benign recurrent lymphocytic meningitis. Cases are typically due to HSV-2, although rare cases are also caused by HSV-1. Many cases meet accepted diagnostic criteria for Mollaret meningitis, and HSV infection is the most common cause of this syndrome. Cases of recurrent meningitis due to HSV should be classified as recurrent HSV meningitis, and the term Mollaret's meningitis should now be reserved for cases of recurrent aseptic meningitis of unknown aetiology.

Approximately 40% of patients with PCR-confirmed recurrent HSV meningitis have a previous history of genital lesions. Anecdotal evidence suggests that aciclovir is effective in the treatment of HSV meningitis, although randomized trials have not been conducted. The majority of patients remain symptom-free for many years, indicating that long-term antiviral prophylaxis may not be appropriate. However, it may be considered for frequent episodes. A randomized, multicentre, clinical trial of long-term suppressive oral valaciclovir following HSV-2 meningitis is currently underway and may help address this issue.

Address for correspondence:
Dr K Tyler, Department of Neurology, University of Colorado Health Sciences Center, Campus Box B-182, 4200 East Ninth Avenue, Denver, CO 80262, USA

E-mail: ken.tyler@uchsc.edu

Received for publication: 29 September 2003
Accepted for publication: 26 November 2003

REFERENCES

1. Whitley RJ. Herpes simplex virus. In: Scheld WM, Whitley RJ, Durack DT (eds). *Infections of the Central Nervous System*, 2nd edn. Philadelphia: Lippincott-Raven, 1997;pp73–89.
2. Baringer JR. Herpes simplex virus encephalitis. In: Davis LE, Kennedy PGE (eds). *Infectious Diseases of the Nervous System.* Oxford: Butterworth-Heinemann, 2000;pp139–164.
3. Whitley RJ, Soong SJ, Linneman C, Jr, Liu C, Pazin G, Alford CA. Herpes simplex encephalitis. Clinical Assessment. *JAMA* 1982;**247**:317–320.
4. Whitley RJ, Roizman B. Herpes simplex virus infections. *Lancet* 2001;**357:**1513–1518.
5. Skoldenberg B, Forsgren M, Alestig K, Bergstrom T, Burman L, Dahlqvist E *et al.* Acyclovir versus vidarabine in herpes simplex encephalitis. Randomised multicentre study in consecutive Swedish patients. *Lancet* 1984;**2**: 707–711.
6. Koskiniemi M, Piiparinen H, Mannonen L, Rantalaiho T, Vaheri A. Herpes encephalitis is a disease of middle aged and elderly people: polymerase chain reaction for detection of herpes simplex virus in the CSF of 516 patients with encephalitis. The Study Group. *J Neurol Neurosurg Psychiatry* 1996;**60**:174–178.
7. Aurelius E, Johansson B, Skoldenberg B, Forsgren M. Encephalitis in immunocompetent patients due to herpes simplex virus type 1 or 2 as determined by type-specific polymerase chain reaction and antibody assays of cerebrospinal fluid. *J Med Virol* 1993;**39**:179–186.
8. Nahmias AJ, Whitley RJ, Visintine AN, Takei Y, Alford CA, Jr. Herpes simplex virus encephalitis: laboratory evaluations and their diagnostic significance. *J Infect Dis* 1982;**145**:829–836.
9. Schiff D, Rosenblum MK. Herpes simplex encephalitis (HSE) and the immunocompromised: A clinical and autopsy study of HSE in the settings of cancer and human immunodeficiency virus-type 1 infection. *Hum Pathol* 1998;**29:**215–222.
10. Mommeja-Marin H, Lafaurie M, Scieux C, Galicier L, Oksendler E, Molina JM. Herpes simplex virus type 2 as a cause of severe meningitis in immunocompromised adults. *Clin Infect Dis* 2003;**37:** 1527–1533.
11. Baringer JR, Pisani P. Herpes simplex virus genomes in human nervous system tissue analyzed by polymerase chain reaction. *Ann Neurol* 1994;**36**:823–829.
12. Barnett EM, Jacobsen G, Evans G, Cassell M, Perlman S. Herpes simplex encephalitis in the temporal cortex and limbic system after trigeminal nerve inoculation. *J Infect Dis* 1994;**169**: 782–786.
13. Davis LE, Johnson RT. An explanation for the localization of herpes simplex encephalitis? *Ann Neurol* 1979;**5**:2–5.
14. Johnson RT. Herpesvirus infections. In: *Viral infections of the nervous system.* 2nd edn. Philadelphia: Lippincott-Raven, 1998;pp133–168.
15. Sanders VJ, Felisan S, Waddell A, Tourtellotte WW. Detection of herpesviridae in postmortem multiple sclerosis brain tissue and controls by polymerase chain reaction. *J Neurovirol* 1996;**2**: 249–258.
16. Whitley RJ, Gnann JW. Viral encephalitis: familiar infections and emerging pathogens. *Lancet* 2002;**359**:507–513.
17. Domingues RB, Tsanaclis AM, Pannuti CS, Mayo MS, Lakeman FD. Evaluation of the range of clinical presentations of herpes simplex encephalitis by using polymerase chain reaction assay of cerebrospinal fluid samples. *Clin Infect Dis* 1997;**25**:86–91.
18. Puchhammer-Stockl E, Popow-Kraupp T, Heinz FX, Mandl CW, Kunz C. Establishment of PCR for the early diagnosis of herpes simplex encephalitis. *J Med Virol* 1990;**32**:77–82.

19. Aurelius E, Johansson B, Skoldenberg B, Staland A, Forsgren M. Rapid diagnosis of herpes simplex encephalitis by nested polymerase chain reaction assay of cerebrospinal fluid. *Lancet* 1991;**337**:189–192.
20. Anderson NE, Powell KF, Croxson MC. A polymerase chain reaction assay of cerebrospinal fluid in patients with suspected herpes simplex encephalitis. *J Neurol Neurosurg Psychiatry* 1993;**56**:520–525.
21. Aurelius E. Herpes simplex encephalitis. Early diagnosis and immune activation in the acute stage and during long-term follow-up. *Scand J Infect Dis Suppl* 1993;**89**:3–62.
22. Lakeman FD, Whitley RJ. Diagnosis of herpes simplex encephalitis: application of polymerase chain reaction to cerebrospinal fluid from brain-biopsied patients and correlation with disease. National Institute of Allergy and Infectious Diseases Collaborative Antiviral Study Group. *J Infect Dis* 1995;**171**: 857–863.
23. Revello MG, Baldanti F, Sarasini A, Zella D, Zavattoni M, Gerna G. Quantitation of herpes simplex virus DNA in cerebrospinal fluid of patients with herpes simplex encephalitis by the polymerase chain reaction. *Clin Diagn Virol* 1997;**7**:183–191.
24. Fomsgaard A, Kirkby N, Jensen IP, Vestergaard BF. Routine diagnosis of herpes simplex virus (HSV) encephalitis by an internal DNA controlled HSV PCR and an IgG-capture assay for intrathecal synthesis of HSV antibodies. *Clin Diagn Virol* 1998;**9**:45–56.
25. Domingues RB, Lakeman FD, Mayo MS, Whitley RJ. Application of competitive PCR to cerebrospinal fluid samples from patients with herpes simplex encephalitis. *J Clin Microbiol* 1998;**36**: 2229–2234.
26. Wildemann B, Ehrhart K, Storch-Hagenlocher B, Meyding-Lamade U, Steinvorth S, Hacke W *et al.* Quantitation of herpes simplex virus type 1 DNA in cells of cerebrospinal fluid of patients with herpes simplex virus encephalitis. *Neurology* 1997;**48**:1341–1346.
27. Skoldenberg B. Herpes simplex encephalitis. *Scand J Infect Dis Suppl* 1991;**80**:40–46.
28. Domingues RB, Fink MCD, Tsanaclis AMC, de Castro CC, Cerri GG, Mayo MS *et al.* Diagnosis of herpes simplex encephalitis by magnetic resonance imaging and polymerase chain reaction assay of cerebrospinal fluid. *J Neurol Sci* 1998;**157:** 148–153.
29. McCabe K, Tyler KL, Tanabe J. Diffusion-weighted MRI abnormalities as a clue to the diagnosis of herpes simplex encephalitis. *Neurology* 2003;**61:**1015–1016.
30. Lai CW, Gragasin ME. Electroencephalography in herpes simplex encephalitis. *J Clin Neurophysiol* 1998;**5:**87–103.
31. Misra UK, Kalita J. A comparative study of Japanese and herpes simplex encephalitides. *Electromyogr Clin Neurophysiol* 1998;**38:**41–46.
32. Ch'ien LT, Boehm RM, Robinson H, Liu C, Frenkel LD. Characteristic early electroencephalographic changes in herpes simplex encephalitis. *Arch Neurol* 1977;**34**:361–364.
33. Brick JF, Brick JE, Morgan JJ, Gutierrez AR. EEG and pathological findings in patients undergoing brain biopsy for suspected encephalitis. *Electroencephalogr Clin Neurophysiol* 1990;**76:**86–89.
34. Misra UK, Kalita J. Neurophysiological studies in herpes simplex encephalitis. *Electromyogr Clin Neurophysiol* 1998;**38**: 177–182.
35. Whitley RJ, Soong SJ, Dolin R, Galasso GJ, Ch'ien LT, Alford CA. Adenine arabinoside therapy of biopsy-proved herpes simplex encephalitis. National Institute of Allergy and Infectious Diseases collaborative antiviral study. *N Engl J Med* 1977;**297**: 289–294.
36. Whitley RJ, Alford CA, Hirsch MS, Schooley RT, Luby JP, Aoki FY *et al.* Vidarabine versus acyclovir therapy in herpes simplex encephalitis. *N Engl J Med* 1986;**314**: 144–149.
37. Lahat E, Barr J, Barkai G, Paret G, Brand N, Barzilai A. Long term neurological outcome of herpes encephalitis. *Arch Dis Child* 1999;**80**:69–71.
38. De Tiege X, Rozenberg F, Des Portes V, Lobut JB, Lebon P, Ponsot G *et al.* Herpes simplex encephalitis relapses in children. *Neurology* 2003;**61:**241–243.
39. Ito Y, Kimura H, Yabuta Y, Ando Y, Murakami T, Shiomi M *et al.* Exacerbation of herpes simplex encephalitis after successful treatment with acyclovir. *Clin Infect Dis* 2000;**30**:185–187.
40. Johnson RT. Acute encephalitis. *Clin Infect Dis* 1996;**23**:219-224; quiz 225–216.
41. Skoldenberg B. Herpes simplex encephalitis. *Scand J Infect Dis Suppl* 1996;**100**: 8–13.
42. Cinque P, Cleator GM, Weber T, Monteyne P, Sindic CJ, van Loon AM. The role of laboratory investigation in the diagnosis and management of patients with suspected herpes simplex encephalitis: a consensus report. The EU Concerted Action on Virus Meningitis and Encephalitis. *J Neurol Neurosurg Psychiatry* 1996;**61**:339–345.
43. Corey L, Adams HG, Brown ZA, Holmes KK. Genital herpes simplex virus infections: clinical manifestations, course, and complications. *Ann Intern Med* 1983;**98**:958–972.
44. Bergstrom T, Vahlne A, Alestig K, Jeansson S, Forsgren M, Lycke E. Primary and recurrent herpes simplex virus type 2-induced meningitis. *J Infect Dis* 1990;**162**:322–330.
45. Aurelius E, Forsgren M, Gille E, Skoldenberg B. Neurologic morbidity after herpes simplex virus type 2 meningitis: a retrospective study of 40 patients. *Scand J Infect Dis* 2002;**34**:278–283.
46. Mollaret P. La meningite endothelio-leucocytaire multirecurrente benigne: dsyndrome nouveau ou maladie nouvelle? *Rev Neurol (Paris)* 1944;**76**:57–76.
47. Tang YW, Cleavinger PJ, Li H, Mitchell PS, Smith TF, Persing DH. Analysis of candidate-host immunogenetic determinants in herpes simplex virus-associated Mollaret's meningitis. *Clin Infect Dis* 2000;**30**:176–178.
48. Schlesinger Y, Tebas P, Gaudreault-Keener M, Buller RS, Storch GA. Herpes simplex virus type 2 meningitis in the absence of genital lesions: improved recognition with use of the polymerase chain reaction. *Clin Infect Dis* 1995;**20**: 842–848.
49. Berger JR. Benign aseptic (Mollaret's) meningitis after genital herpes. *Lancet* 1991;**337**:1360–1361.
50. Lortholary O, Rozenberg F, Perronne C, Djebbour S, Leport C, Vilde JL. Herpes simplex virus type 2 DNA in cerebrospinal fluid of a woman with recurrent meningitis. *Clin Infect Dis* 1993;**17**:941–942.
51. Jensenius M, Myrvang B, Storvold G, Bucher A, Hellum KB, Bruu AL. Herpes simplex virus type 2 DNA detected in cerebrospinal fluid of 9 patients with Mollaret's meningitis. *Acta Neurol Scand* 1998;**98**: 209–212.
52. Monteyne P, Sindic CJ, Laterre EC. Recurrent meningitis and encephalitis associated with herpes simplex type 2: demonstration by polymerase chain reaction. *Eur Neurol* 1996;**36**:176–177.
53. Tedder DG, Ashley R, Tyler KL, Levin MJ. Herpes simplex virus infection as a cause of benign recurrent lymphocytic meningitis. *Ann Intern Med* 1994;**121**:334–338.
54. Chambers ST, Powell KF, Croxson MC, Krishnan S, Weir RP. Demonstration of herpes simplex type 2 in the cerebrospinal fluid of two patients with recurrent lymphocytic meningitis. *N Z Med J* 1994;**107**:367–369.
55. Bergstrom T, Alestig K. Treatment of primary and recurrent herpes simplex virus type 2 induced meningitis with acyclovir. *Scand J Infect Dis* 1990;**22**:239–240.
56. Cohen BA, Rowley AH, Long CM. Herpes simplex type 2 in a patient with Mollaret's meningitis: demonstration by polymerase chain reaction. *Ann Neurol* 1994;**35**:112–116.
57. Bachmeyer C, de la Blanchardiere A, Lepercq J, Dhote R, Grateau G, Detilleux M *et al.* Recurring episodes of meningitis (Mollaret's meningitis) with one showing an association with herpes simplex virus type 2. *J Infect* 1996;**32**:247–248.